

LOST and FOUND: Fremdkörper im Becken

Andreas Salat

ISDS-Tagung 13.06.2016
Brac



MEDICAL
UNIVERSITY
OF VIENNA



Center Of Competence

Disclaimer

Youtube
**Top 10 Craziest Foreign Objects Found
Stuck In A Rectum**

Liveleak.com
**Eel removed from new Zealand Mans
rectum**

Systematik

Autoerotisch

(Dildos, Zuckerdosen, Maiskolben, Nektarine,...)

Bodypacker

(Kokain in Kondomen)

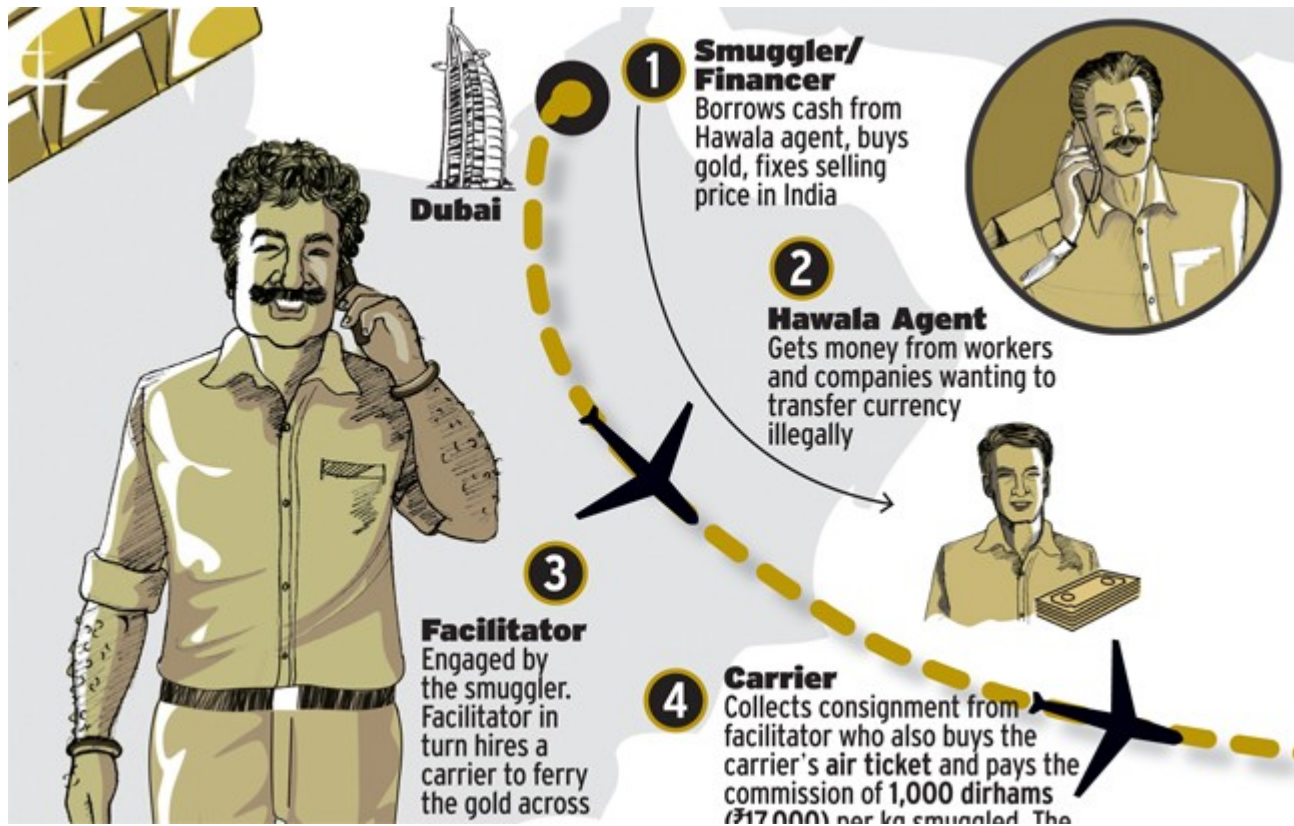iatrogen.

(Schrauben, SNM-Drähte, Knochen,...)

Systematik



Systematik



Systematik

Autoerotisch

(Dildos, Zuckerdosen, Maiskolben, Nektarine,...)

Bodypacker

(Kokain in Kondomen)

iatrogen.

(Schrauben, SNM-Drähte, Knochen,...)

Systematik

Stift A. personal communication

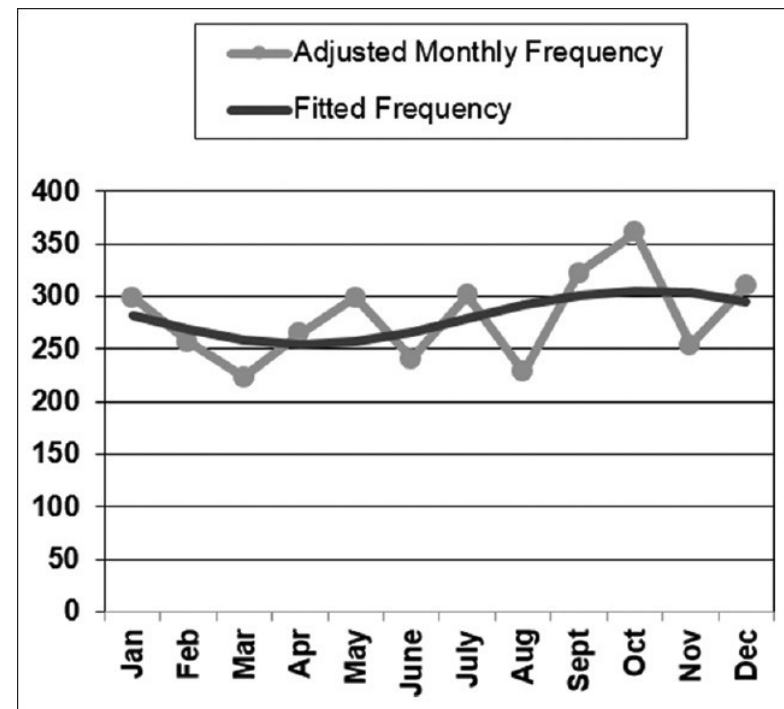


saisonale Schwankungen

Pathak R et al N Am J Med Sci. 2016 Apr;8(4):191-3

USA
Nationwide
n=3359 (3 Jahre)

Further studies would be required to verify whether our findings of a higher incidence in the fall season are reflective of acute changes in the length of the days, climate, sleep-wake cycle, or decreased sexual intercourse at this time of the year.



Mann vs. Frau

Odagiri H et al. Digestion. 2015;92(3):165-70

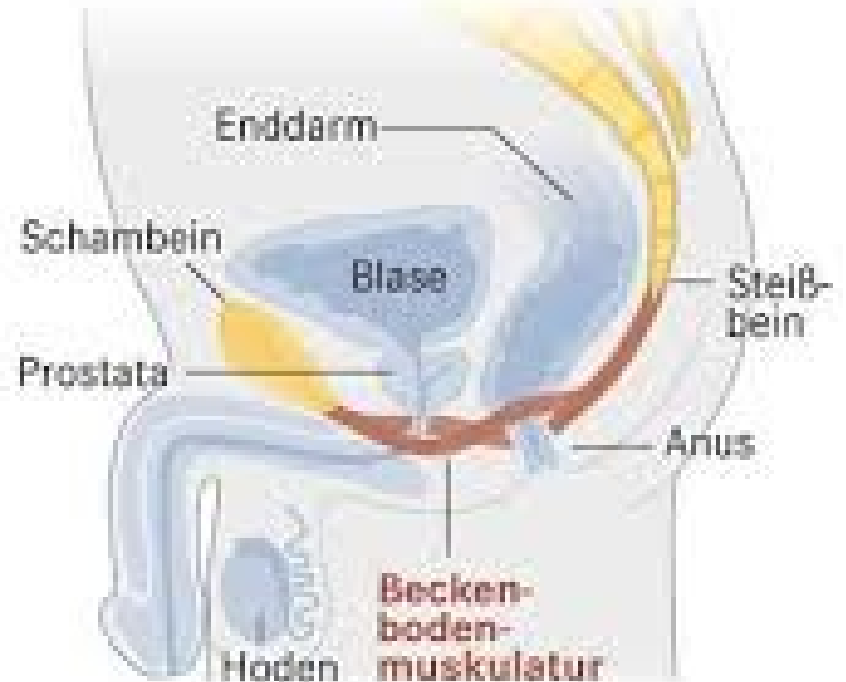
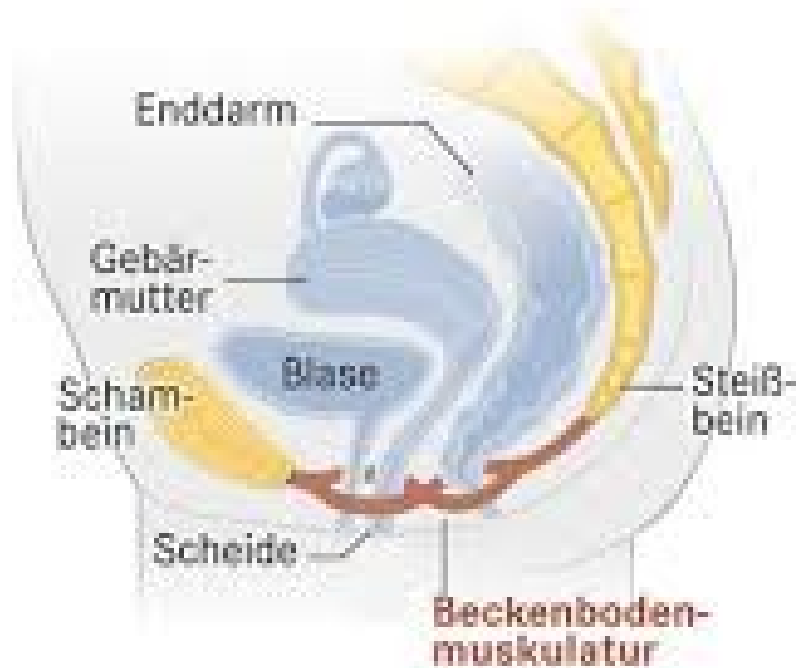
Japan, nationwide, n=666 (6 Jahre)

Männer 81,1%

In-hospital Sterblichkeit 1,2%

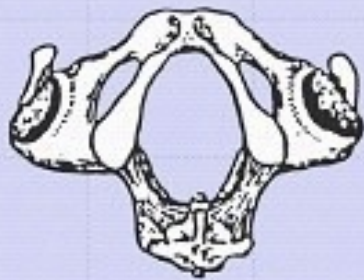
Compared with males, females had a significantly higher proportion of in-hospital death (0.4 vs. 4.8%, $p = 0.001$), perforation and peritonitis (5.2 vs. 12.8%, $p = 0.004$), and sepsis (1.1 vs. 4.0%, $p = 0.04$).

Anatomische Überlegungen

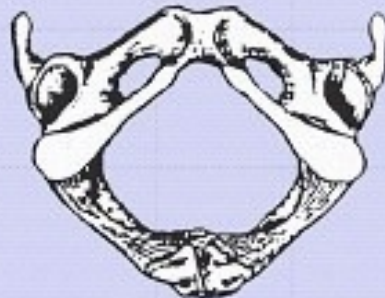


Anatomische Überlegungen

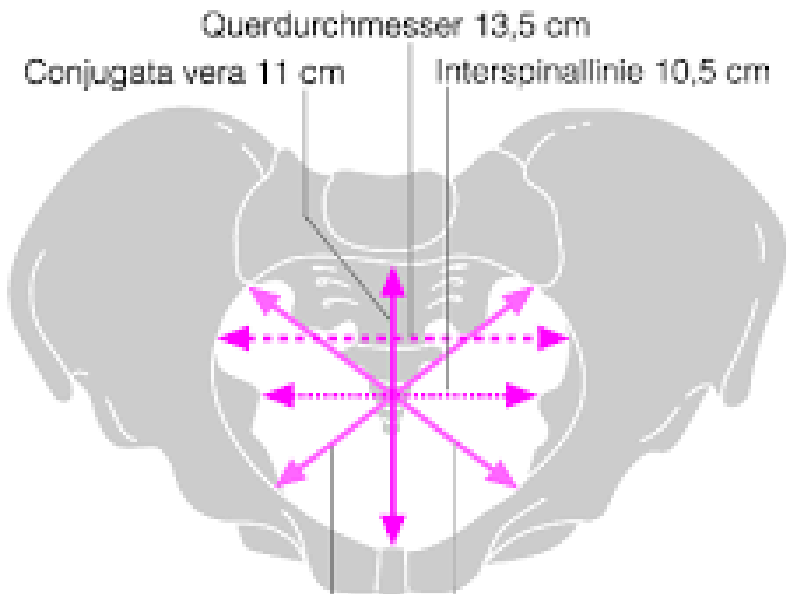
Becken von Unten



Männliches Becken



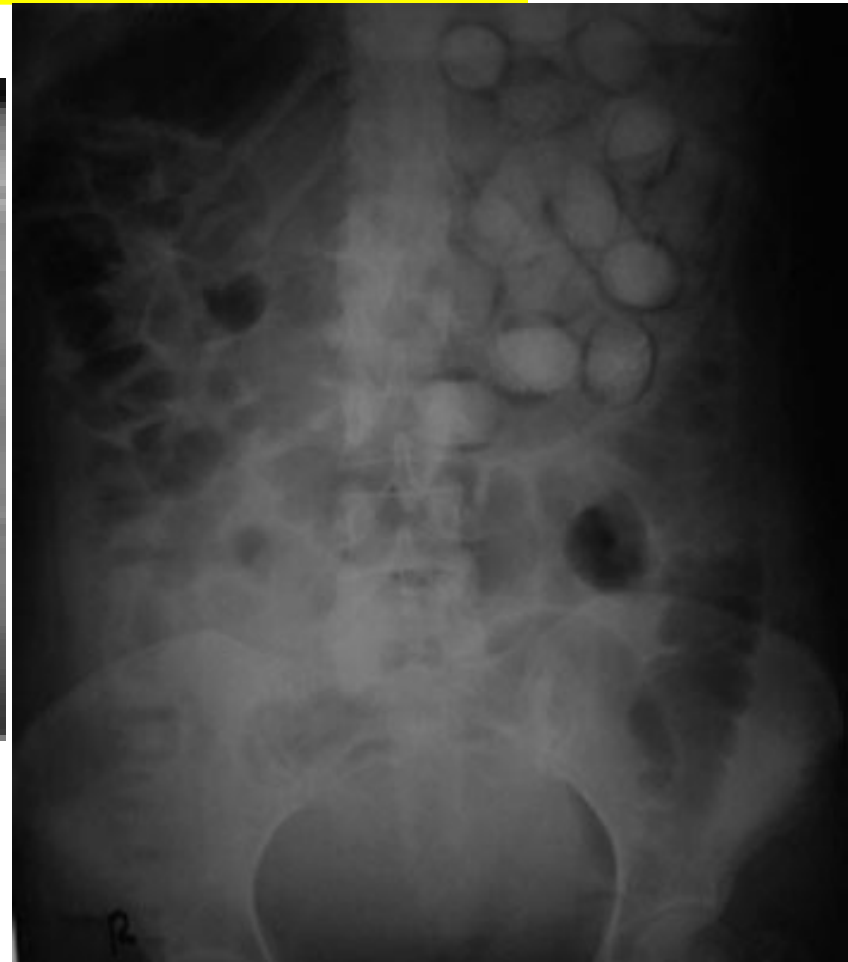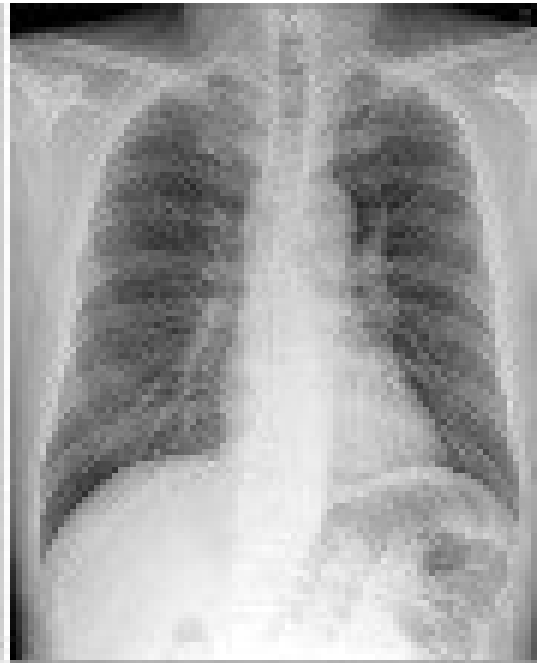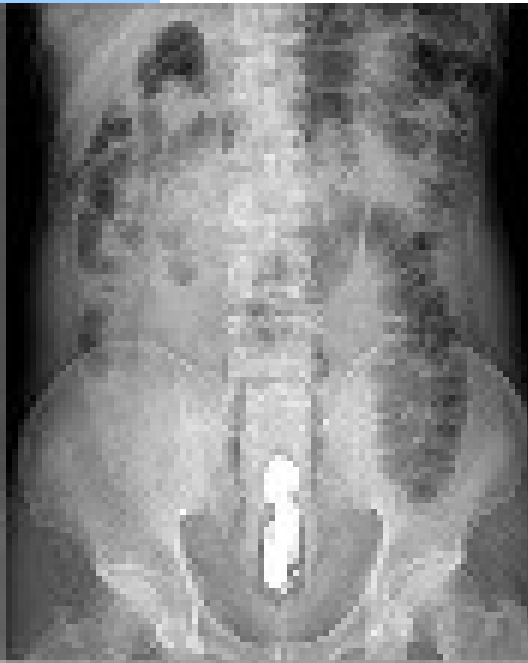
Weibliches Becken



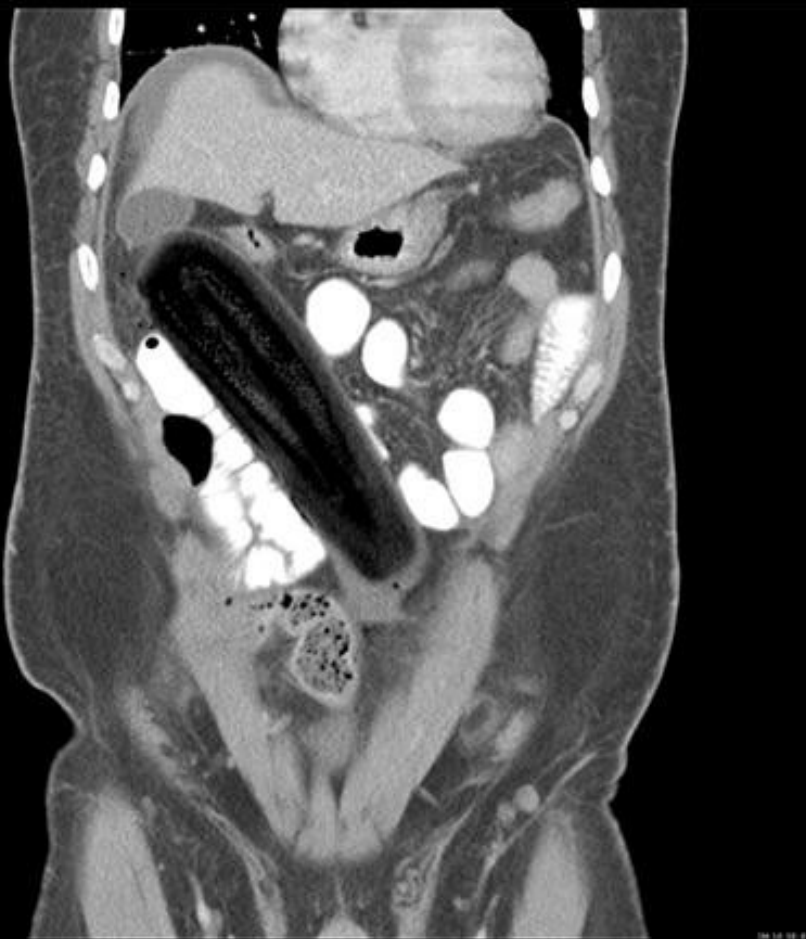2. schräger Durchmesser 12,5 cm

1. schräger Durchmesser 12,5 cm

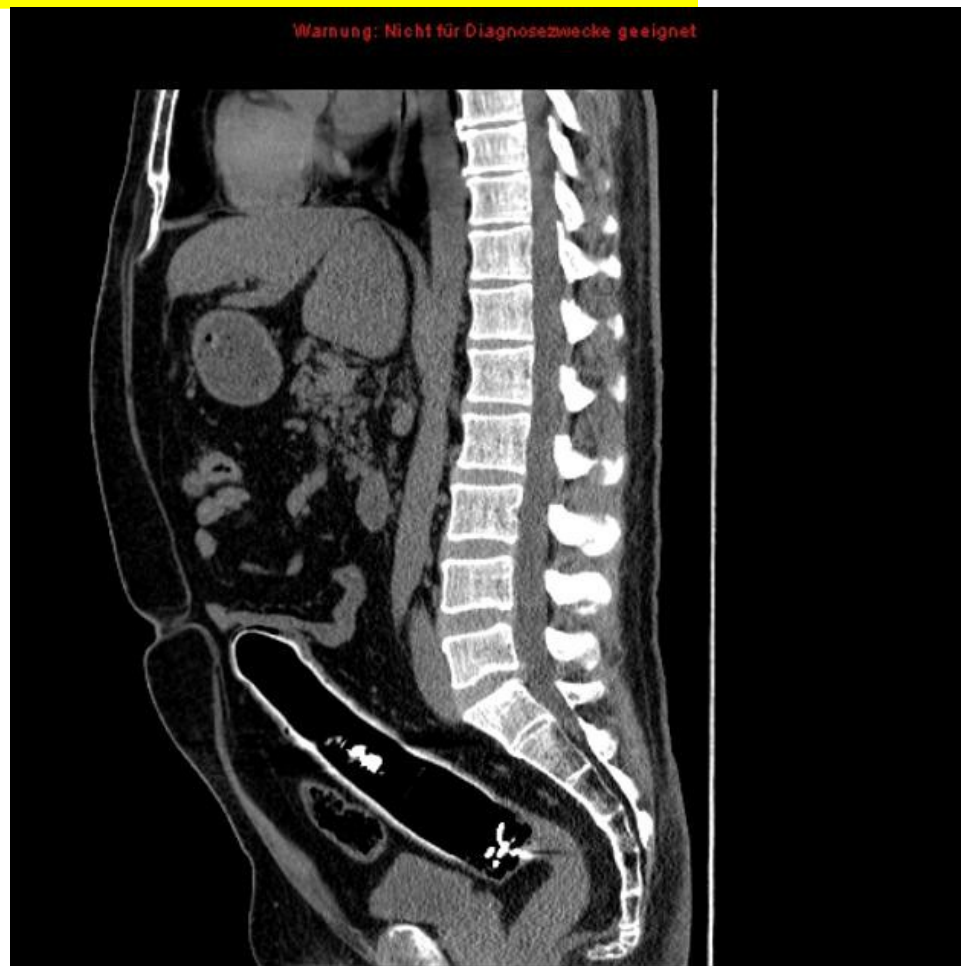
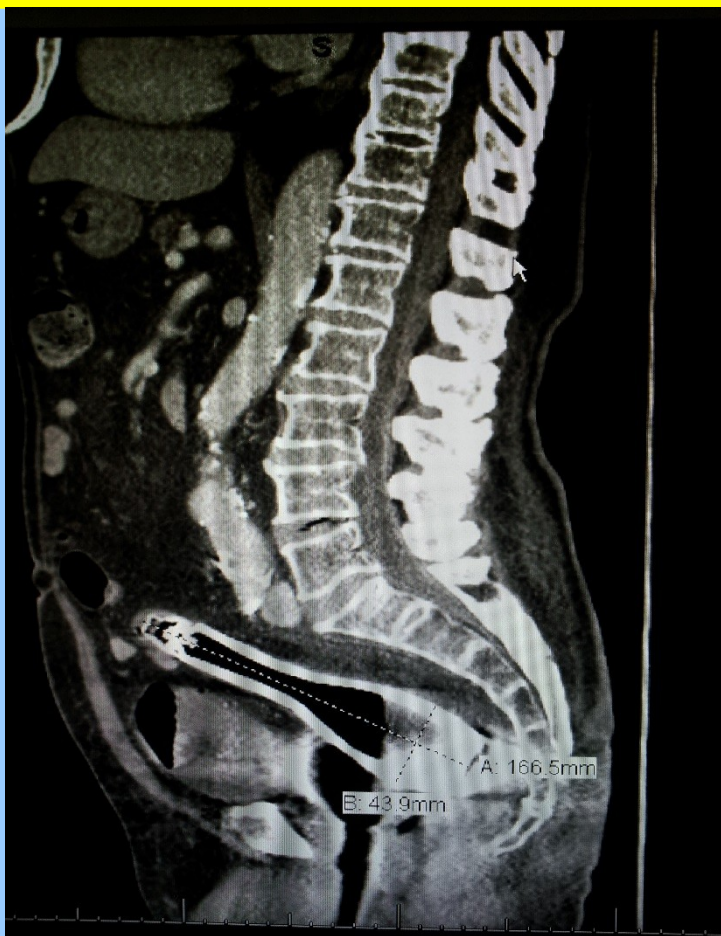Diagnostik - Abdomen leer



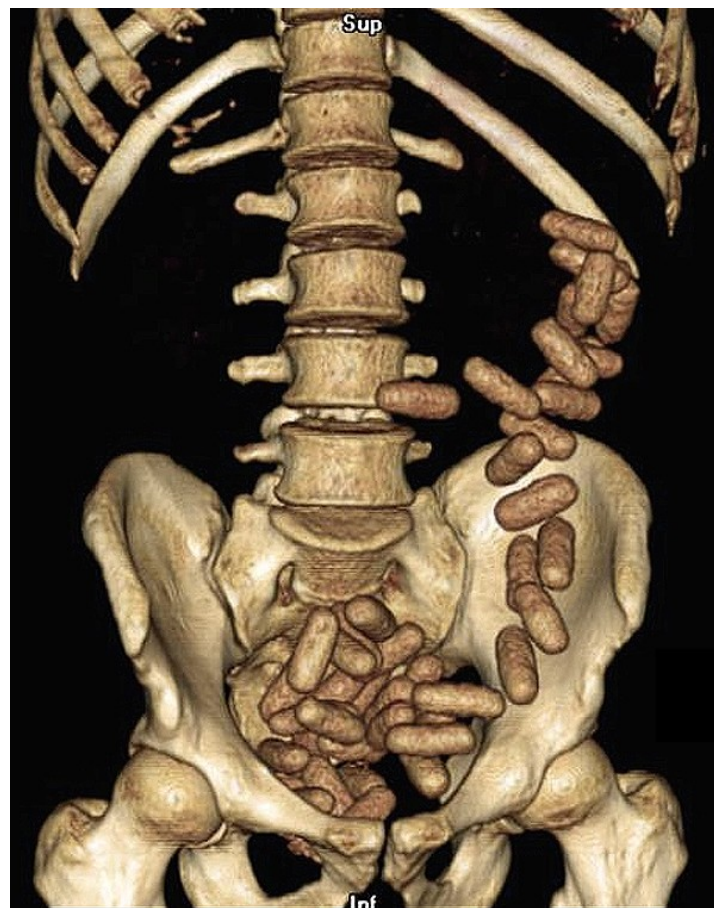
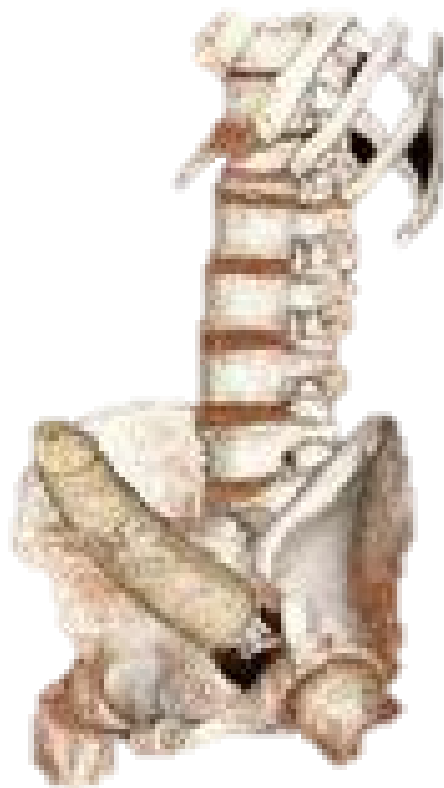Diagnostik - CT



Diagnostik - CT



Diagnostik – 3D-CT



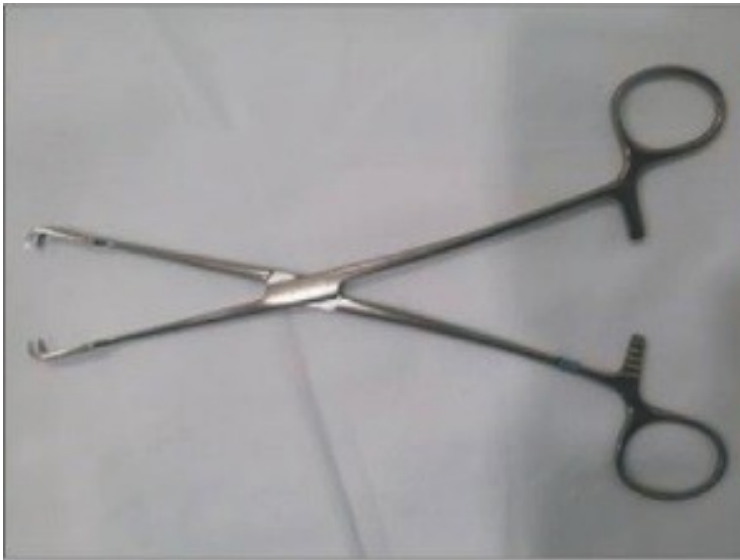Extraktion

MacDonald AP. *Practitioner* 1961; **186**: 370–371



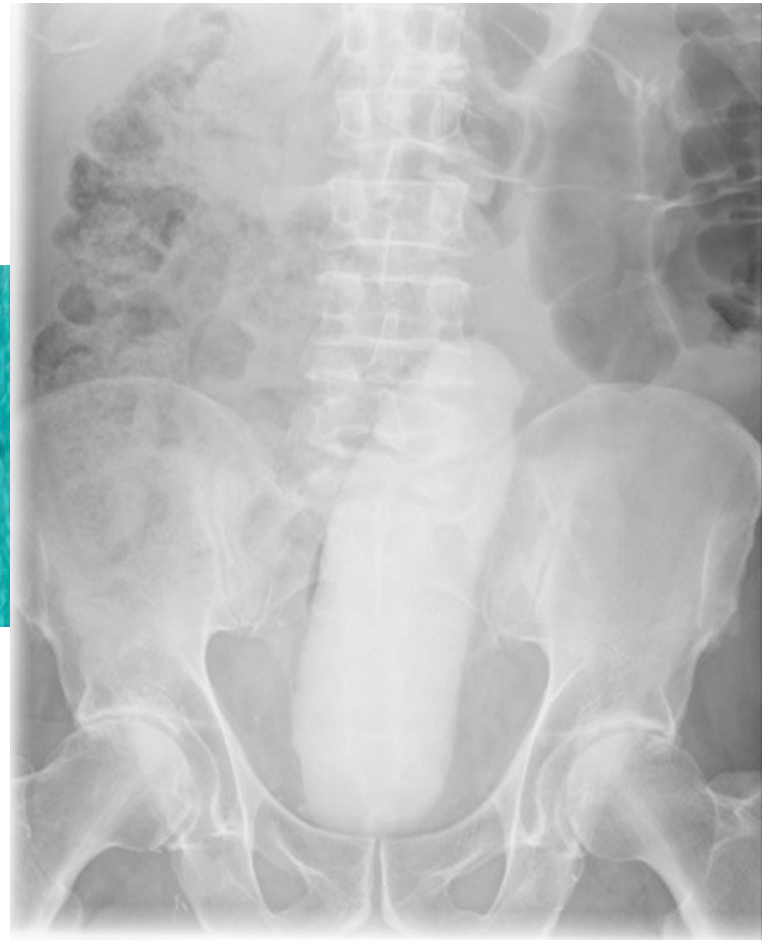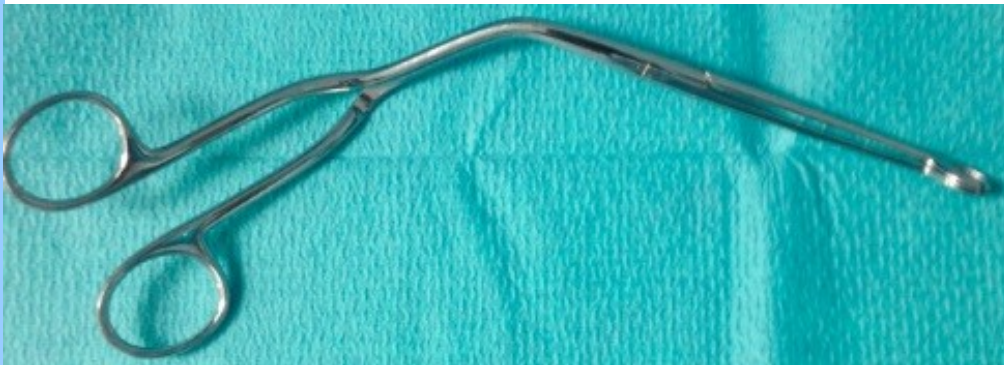Extraktion

Lim KJ et al. Intest Res. 2015 Oct; 13(4): 355–359.



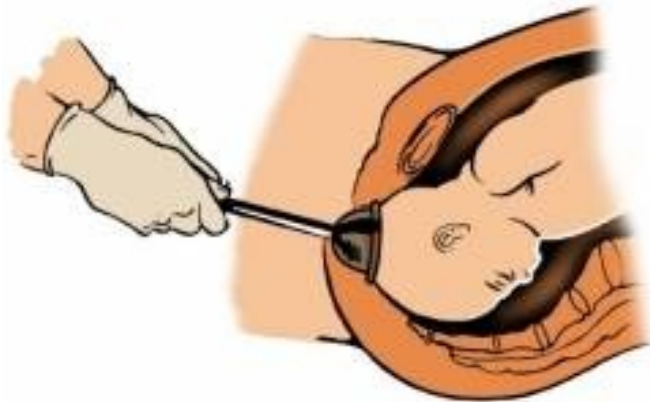Extraktion

Obinwa O et al. Int J Surg Case Rep. 2015;15:96-8



Saugglocke

Johnson SO et al. Dis Colon Rectum 1996;39(8):935-7



Use of the delivery vacuum extractor provided a safe, cost-effective method of glass foreign body removal by the transanal route. Literature review found no other reports of rectal foreign body removal by this method.

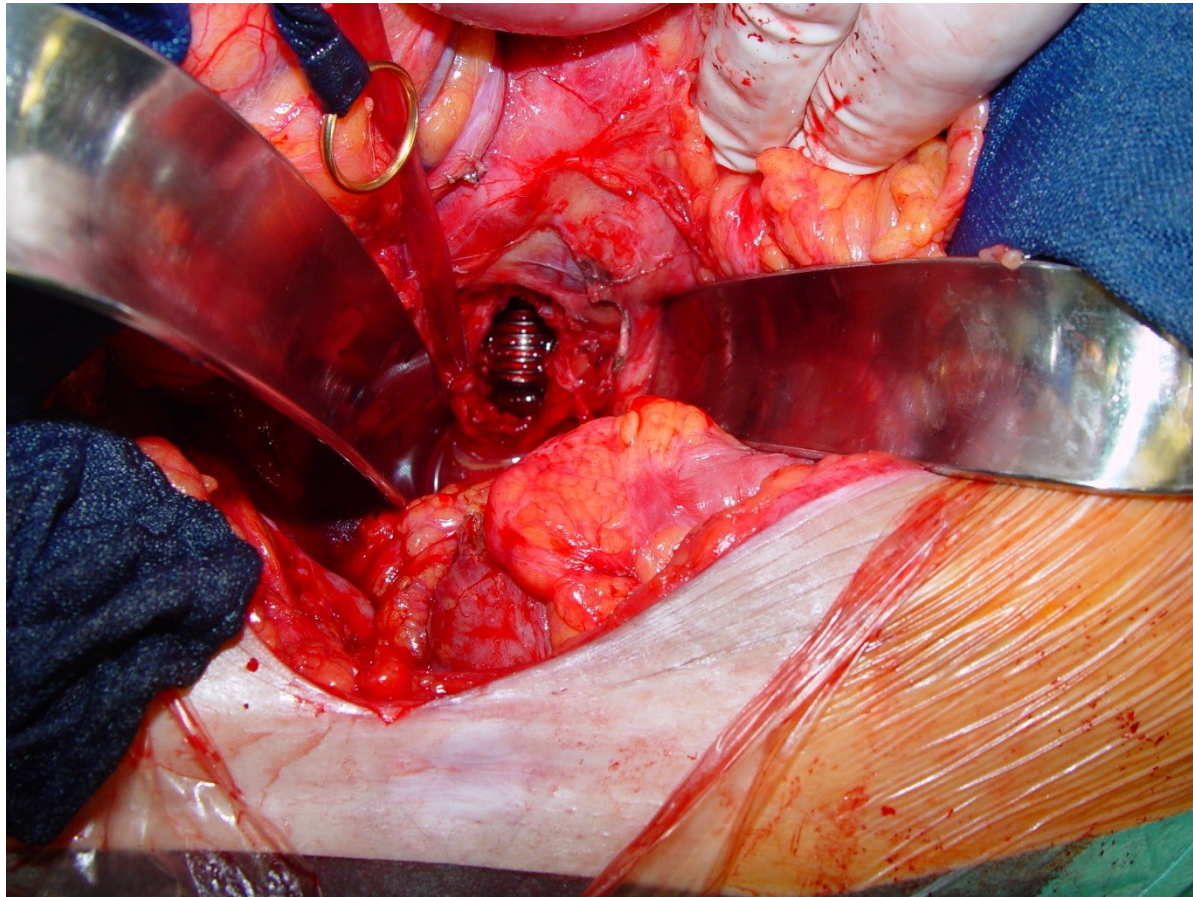
Laparotomie

In a series of 48 patients reported successful extraction in the emergency department in 31/48 (63%) patients and operating room extraction in 18/48 (37%) patients, 12 cases were simply extracted under anaesthesia, five patients required primary repair and diverting colostomy 5/48 (**10,4%**) for rectal perforation and one required primary repair of an external anal sphincter laceration.

Andere Serie: 7/30 (**23%**)

Chronischer Abszeß

Stift A. personal communication



TAKE HOME

„Alles gibt`s“

Selten Iatrogen, meist autoerotisch
Perforation ausschließen
Schamgefühl achten
Chronischer Abszeß nach
Voreingriffen